



# Adventures in Prosthetics

## A Contact Lens Approach to Improving Cosmetic Appearance

Jamie Kuhn, O.D., FAAO, FSLS  
Kokopelli Eye Institute  
Glendale, Arizona, USA



# Prosthetic Contact Lens Options

- Tinted Soft Lenses
- Stamped-design Soft Lenses
- Hand-painted Soft Lenses
- Stamped-design Rigid Lenses
- Hand-Painted PMMA Rigid Lenses

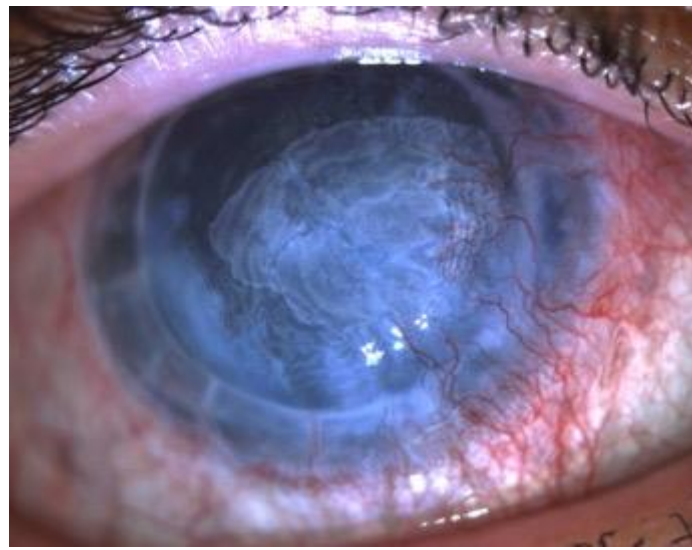


# Case #1: 45yo Indian female

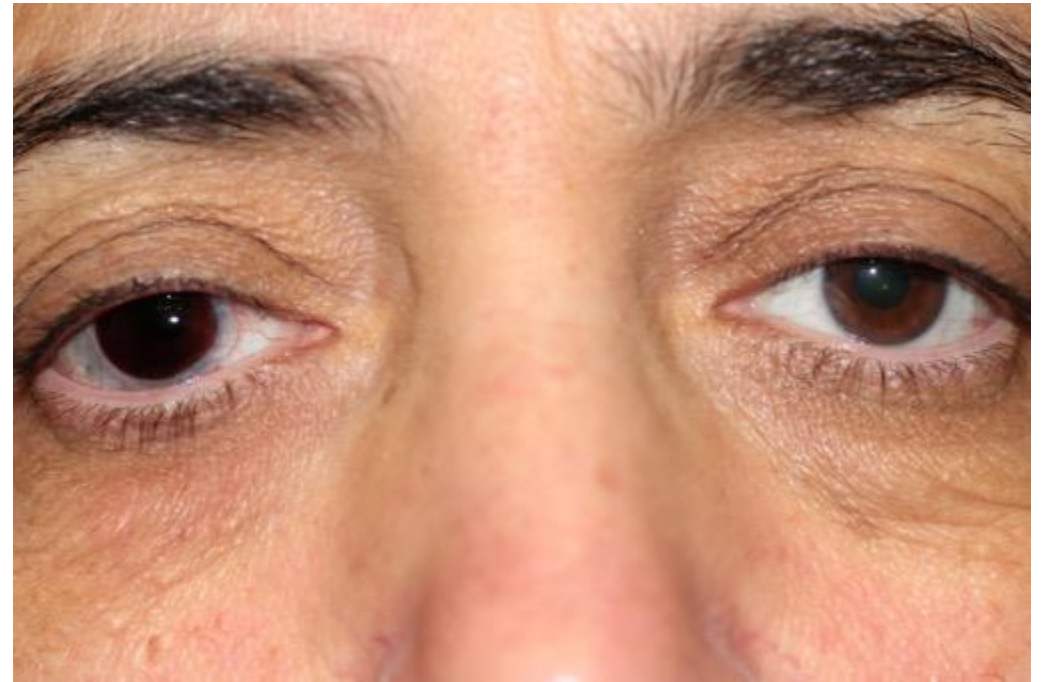
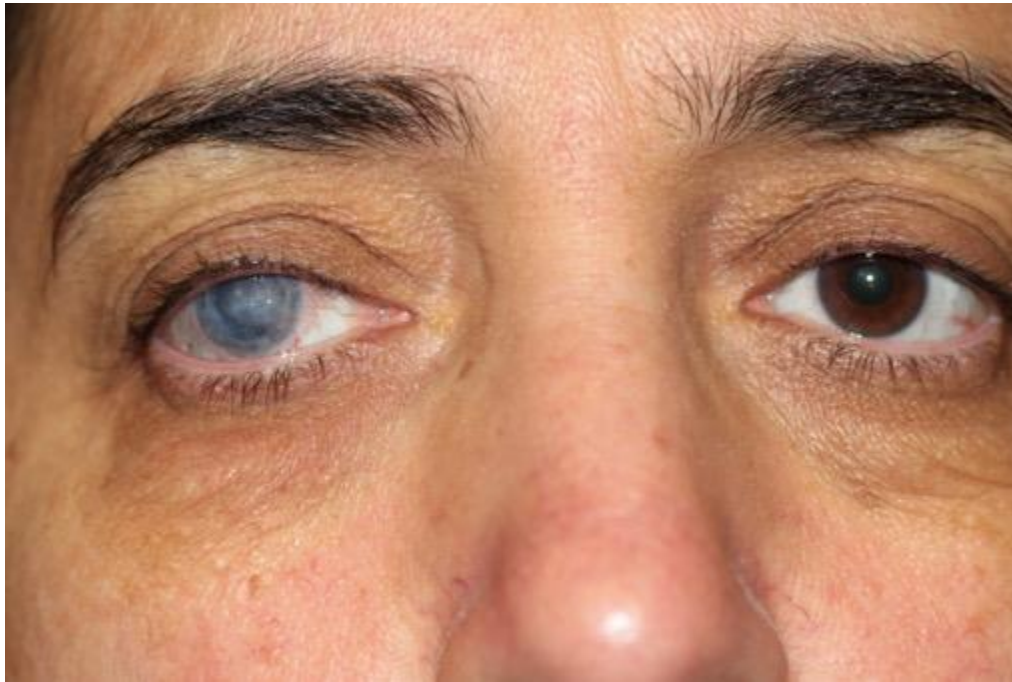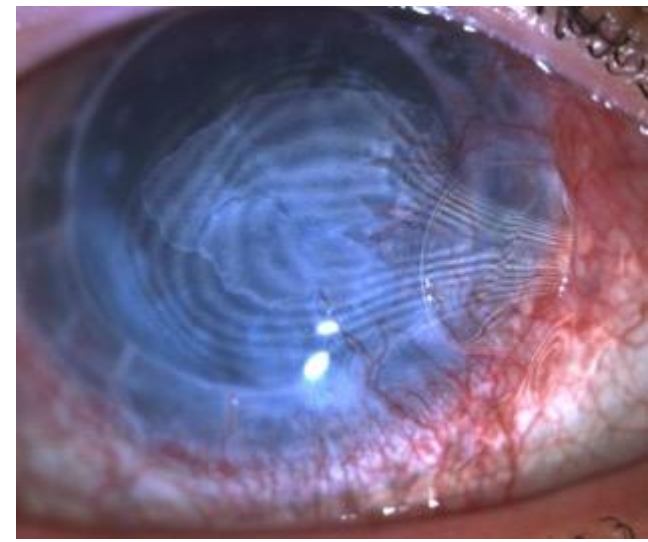
- Ocular history OD:
  - Corneal graft and IOL exchange 2' to MVA in 2000
  - Second graft and IOL dislocation in 2012 2' to fall
  - Generalized corneal opacification with increased scleral injection since injury in 2012
    - No usable vision remaining
    - Enucleation recommended to pt, but declined
  - Bouts of increased IOP OD since 2000, treated with Diamox PRN
- Ocular history OS: unremarkable
- \*Pt is a *never* contact lens wearer







**Case #1**

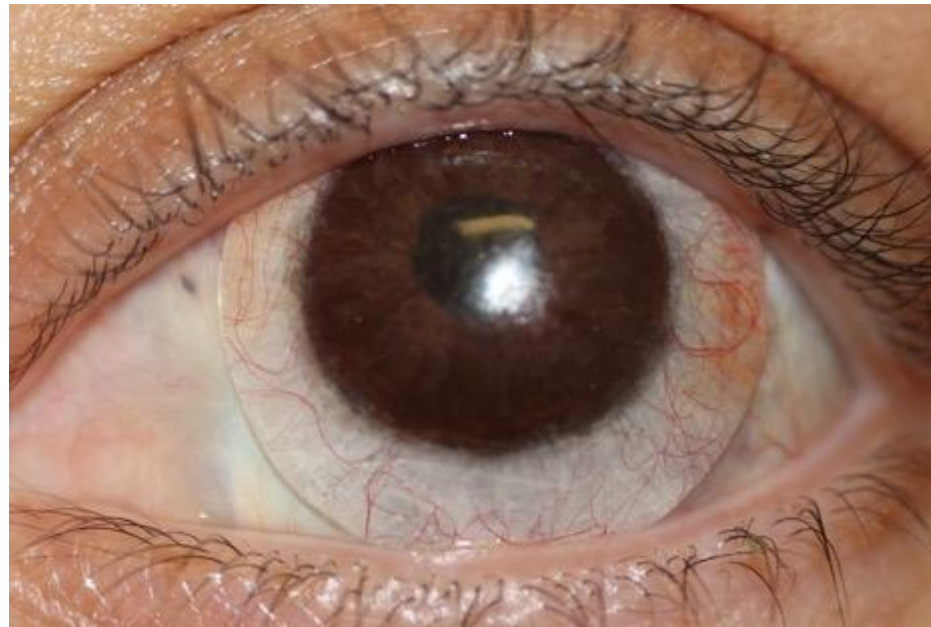
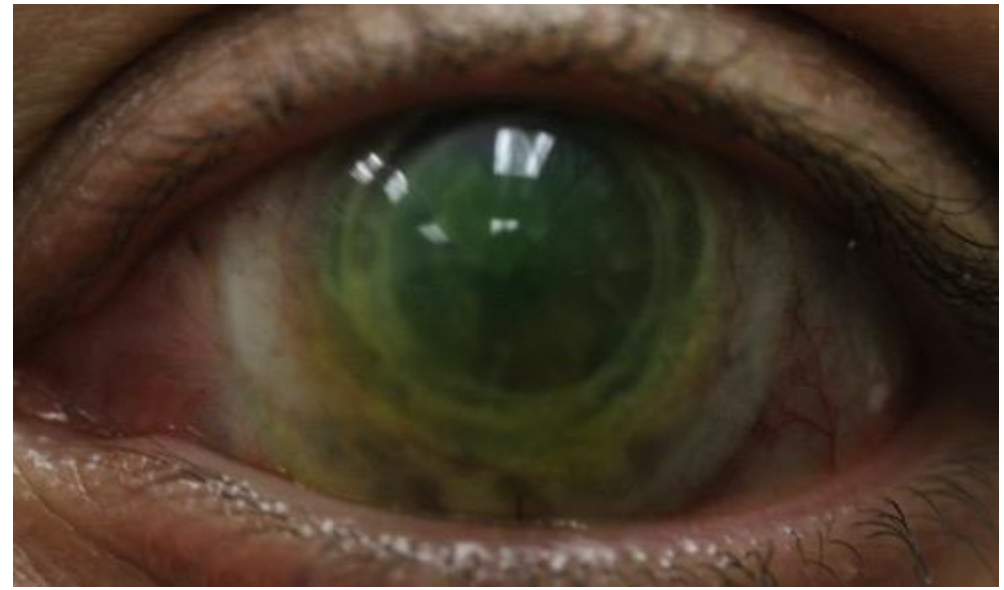
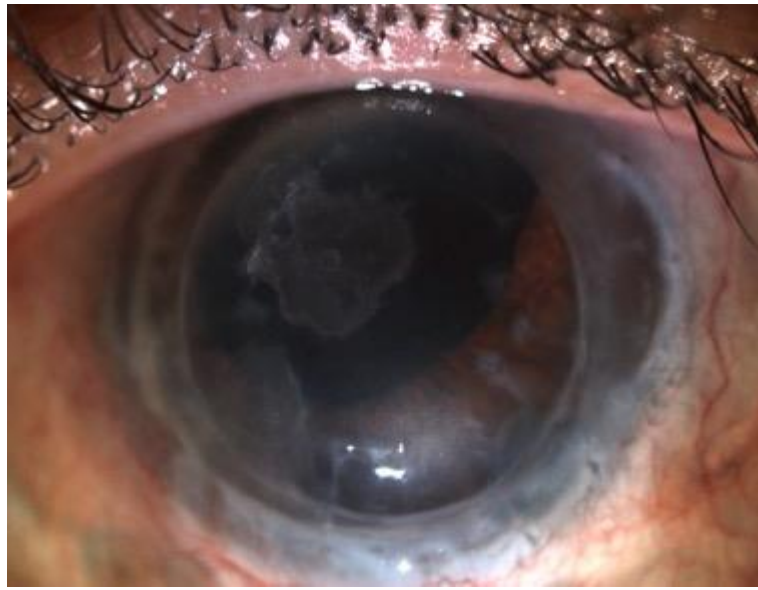

# Case #2 48yo African-American female

- Presents for a consult to improve cosmesis of her left eye
  - Patient also reports extreme light sensitivity since trauma to OS
  - Previously a singer, but no longer “goes out” due to severe discomfort with appearance
  - Referred by outside provider for consultation
- Occupation: None, disabled
- Avocation: Singing, children
- Allergies: NKDA
- Ocular history OD: unremarkable
- Ocular history OS:
  - Retinal detachment with 2 subsequent surgical repairs (including scleral buckle)
  - Corneal graft (x5) and IOL exchange 2’ complications from retinal surgeries
  - Corneal opacification and increased scleral injection since surgeries
  - Bouts of increased IOP and extreme pain
  - No usable vision
- \*Pt is a *former* soft contact lens wearer





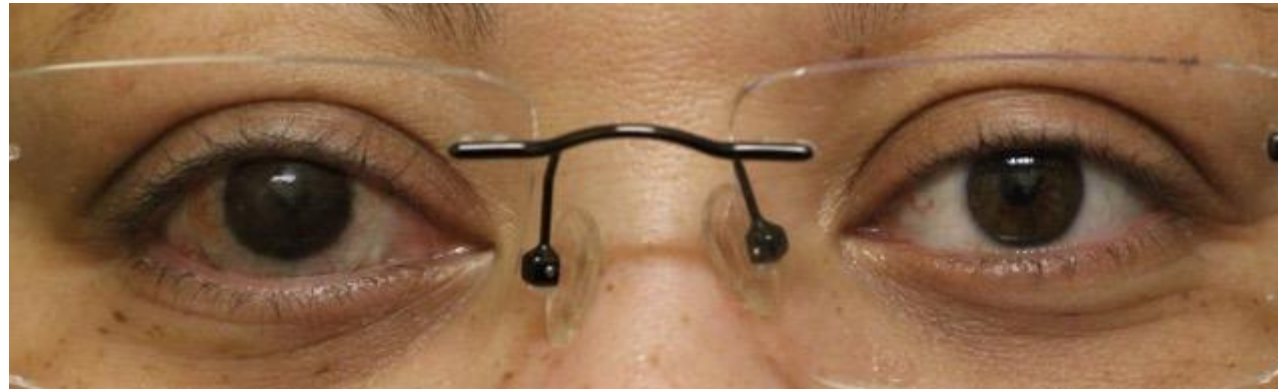
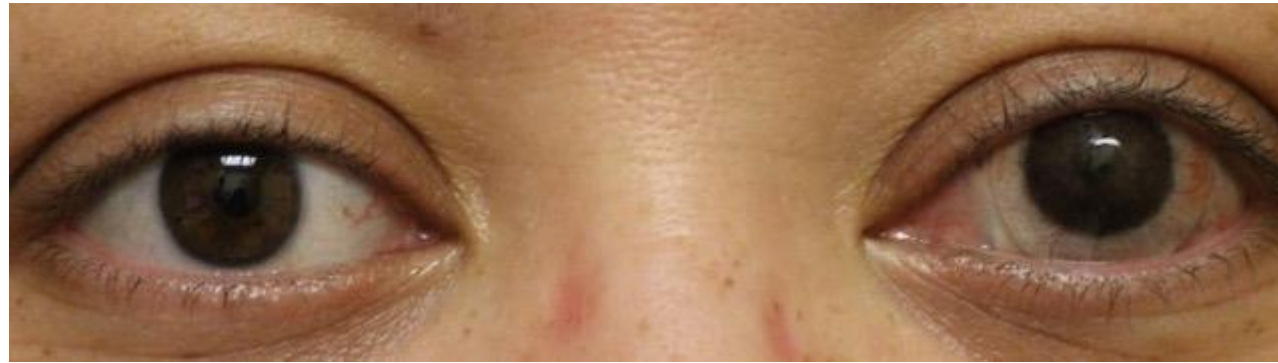
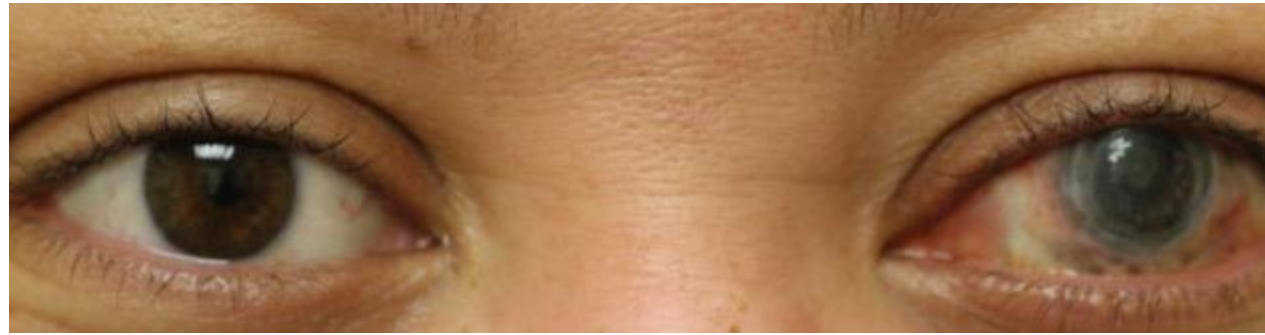**Case #2**





**Case #2**





# Take-Aways

- Prosthetic ocular devices are routinely used to keep the socket tissues in good health, as well
  - Atrophy of socket tissues
  - Infections
  - Mechanical irritation
  - Dryness
- Both cases highlight the importance of addressing cosmesis
  - This is MORE than just skin-deep
- Psychological impact of ocular loss of deformity can be addressed with a properly-fitting prosthetic device

